

## Clinical Evaluation of Hyperpigmentation Through Monopolar / Bipolar Radiofrequency and Fractional Microneedle Rf in Fitzpatrick Iii–V

Ruhal Javed<sup>1</sup> Danial bashir<sup>1</sup> Muhammad Jahanzeb<sup>2</sup> Minahil Imtiaz<sup>1</sup> Fariha Ambreen<sup>2</sup> Qudsia Dilshad<sup>1</sup>

<sup>1</sup> Students

<sup>2</sup> University Teachers

### Abstract

This study evaluated the comparative benefit and safety of monopolar radiofrequency (RF), bipolar RF and fractional microneedling radiofrequency (FMR) in post inflammatory hyperpigmentation (PIH) in subjects of Fitzpatrick skin types III-V. This was a prospective comparative quasi-experimental study conducted at various dermatology or aesthetic centers in Pakistan over a period of 4 months. 77 subjects (25 to 60 years) were distributed in three different treatment groups and the three executed 4 treatment sessions at two-to-three-week intervals. Clinical outcomes were wrinkles, skin laxity, reduction of PIH, patient satisfaction, pain scores, erythema, edema, and adverse effects. One-way ANOVA, Chi-square, Tukey post hoc tests, and Pearson correlation were performed in SPSS 26.0 for statistical analyses. The results showed highly significant difference between the treatment modalities ( $p < 0.001$ ). Compared to the other groups, FMR group gave the best results for wrinkle reduction ( $45.6\% \pm 7.4$ ) and skin laxity ( $42.8\% \pm 6.9$ ) and 69.2% fulfilled higher than 50% boost in PIH seriousness within the FMR group. Moderate clinical efficacy, with increased tolerability, was noted with bipolar RF and comparatively decreased efficacy, with minimal downtime, was noted with monopolar RF. Somewhat higher pain scores did not affect patient satisfaction, which was highest in the FMR group. The most common complication was transient erythema and edema but there was no long-term PIH or severe complication noted. The outcomes suggest that FMR offers the best modality for patients of darker skin types for hyperpigmentation, skin texture and skin laxity, while bipolar RF offers a favorable compromise in terms of treatment efficacy and tolerability. All three RF-based modalities were safe and clinically useful for Fitzpatrick skin types III-V, and if performed appropriately as an isolated treatment.

**Keywords:** Radiofrequency, hyperpigmentation, post-inflammatory hyperpigmentation, Fitzpatrick skin type, fractional microneedling radio frequency, monopolar RF, bipolar RF, skin rejuvenation.

### Introduction

Hyperpigmentation is among the most widespread skin condition that afflicts people of any age and race worldwide and is specifically observed in people with darker skin coloring. It is marked by an overproduction of melanin and the deposition of the pigment into the epidermis or dermis resulting in cosmetically unsightly dark spots on the skin (Grimes et al., 2009). Post-inflammatory hyperpigmentation (PIH) is now a common occurrence after inflammatory dermatoses, acne vulgaris, eczema, as well as trauma, burns, cosmetic surgical intervention and laser intervention. People of Fitzpatrick types III-V are more susceptible as melanocytes of dark skin are more sensitive to inflammatory compounds and heat (Alexis et al., 2007).

The psychosocial consequences of hyperpigmentation are high since victims tend to suffer anxiety, self-dissatisfaction with appearance, low self-esteem, and withdrawing socially (Davis and Callender, 2010). Epidemiological findings suggest that pigmentary disorders are one of the

most popular causes of consultations in pigmented skin in skin color populations (Taylor, 2023). Additionally, poor protection against UV and the usage of such products which are unregulated and unverified remains a way of worsening pigmentary complications in the South Asian populations (Taylor, 2023).

Pathophysiology PIH is associated with an inflammatory cascade that includes prostaglandins, leukotrienes, cytokines and reactive oxygen species that activate melanocytes and melanin production. The surplus melanin is then passed on to the keratinocytes which leaves behind permanent hyperpigmented lesions (Grimes et al., 2009). Melanogenesis is even increased by ultraviolet radiation, hormones, oxidative stress and environmental pollutants, and the pigmentary changes are even exacerbated.

Radiofrequency (RF)-based aesthetic procedures have become more popular in recent years due to the good safety profile they have with dark skin types. RF devices are chromophore independent and thus less prone to epidermal damage and post procedural PIH unlike laser therapies (Kwon et al., 2018). The monopolar RF is associated with deeper dermal heating effects compared to the bipolar RF, which is why it is employed in skin tightening and dermal remodeling, whereas bipolar RF can be used with more control and safety due to superficial dermal heating (Alhaddad et al., 2019).

Fractional microneedling radiofrequency (FMR) is the combination of microneedling with the delivery of RF energy in insulated needles, which forms a controlled thermal area in the dermis and spares the epidermis. Technology induces collagen remodeling, neolastogenesis and epidermal turnover that result in a skin texture, acne scar, wrinkles and pigmentation (Gold et al., 2012). Past research indicated that FMR correlates with a low probability of persistent PIH, which is why it is very appropriate with Fitzpatrick III-V skin (Chae et al., 2015).

Although there is growing clinical interest in RF technologies, the comparative evidence of the use of monopolar RF, bipolar RF, and FMR in the treatment of hyperpigmentation of darker skin has been limited. Fragmentation: It is noted that anecdotal experience is still used by most clinicians as opposed to evidence-based treatment guidelines. Consequently, this was done to carry out a clinically comparative analysis of the efficacy, safety and patient satisfaction rates of monopolar RF, bipolar RF and FMR in Fitzpatrick physique III-V individuals.

#### Literature Review

Past reports have proven that following inflammation, post-inflammatory hyperpigmentation is relatively high in people with Fitzpatrick skin type III—V due to augmented melanocyte function and the growth of melanin after inflammation (Grimes et al., 2009). According to Alexis et al. (2007), pigmentary disorders are one of the most frequent reasons that result in dermatological visits among South Asians and Africans.

Tan et al. (2021) compared the efficacy of fractional microneedling radiofrequency in acne scar patients with Fitzpatrick skin type III-V. The analysis indicated statistically significant differences in the severity of the scars between the baseline and after the three sessions of treatments ( $p < 0.01$ ). Likewise, a multicentral clinical trial was carried out in Gold et al. (2012) study with 35 participants that had acne scars and dyschromia. Their results indicated that pigmentation abnormalities were considerably reduced and the wrinkle scores improved significantly with the treatment of FMR.

Chae et al. (2015) compared the bipolar RF to fractional CO<sub>2</sub> laser therapy in Asian patients and found no significant difference between the two groups in the change of pigmentation and skin texture. Nevertheless, post-inflammatory hyperpigmentation This finding was heavily favorable in the laser-treated group ( $p < 0.01$ ) reflecting the better safety of the RF-based treatment modalities.

Pathmarajah et al.(2022) compared FMR with patients having acnes focus and PIH and reported high reduction in the values of melanin index ( $p < 0.01$ ) as well as scar depth ( $p < 0.001$ ). Notably,

there were no cases of persistent PIH. Alhaddad et al. (2019) have also shown that monopolar RF has a considerable effect on skin elasticity and dermal remodeling but can also have an acceptable safety profile.

A study by Kwon et al. (2018) assessed the efficacy of combination of fractional microneedling RF and Q-switched Nd:YAG laser treatment and discovered that changes in the melanin index and hemi-MASI scores were much higher than those in the monotherapy of laser treatments. On the same note, Kwon et al. (2018) and Lee et al. (2021) found synergistic effects of RF microneedling and laser therapy to yield better pigmentation results and skin wrinkles.

Niaz et al. (2025) did a Systematic Review to understand the effectiveness and safety of Fractional Radiofrequency Microneedling (FRM) as a stand-alone non-surgical technique for Acne Scar Management. The review comprised 17 studies with 481 patients, and they found FRM to be withstanding as a minimally invasive treatment modality for enhanced acne scars and skin rejuvenation with an ample level of safety. The authors also pointed out that regardless of scar type, FRM had good clinical outcomes, but more RCTs are needed to provide standardized treatment parameters.

Chae et al. (2015) evaluated FMR in patients whose skin is of type III-V according to Fitzpatrick scale and found that following four treatment sessions, indicators of melanin index and wrinkle reduction were significant. Side effects were mild and temporary, and there was no PIH in the long-term. Similarly, Tan et al. (2021) showed a high level of improvement in acnes scars, skin texture, and skin elasticity after RF microneedling in participants with Chinese skin.

Together this body of literature indicates that RF-based technologies offer superior dermal remodeling and pigmentation enhancement and a low risk of pigmentary complications. Nonetheless, there is a lack of direct comparative clinical data between monopolar RF, bipolar RF and FMR in Fitzpatrick III-V skin. The current study covers this gap by providing a comparative treatment of these modalities by their effectiveness, safety, and patient satisfaction that are comparative to each other.

### **Data and Methodology**

Quasi-experimental comparative study was conducted over a period of four months in several dermatological and aesthetic centers in Pakistan. The participants (77) of ages 25-60 had Fitzpatrick skin type III-V, exhibiting post-inflammatory hyperpigmentation, wrinkles, skin laxity and texture irregularities.

They were divided into three treatment conditions monopolar RF, bipolar RF, and fractional microneedling RF (FMR). All the participants received four treatment sessions separated by two to three weeks as per the treatment modality allocated.

### **Inclusion Criteria**

The subjects were patients aged between 25-60 years who had Fitzpatrick skin-types of III-V and characteristic clinical appearance of hyperpigmentation, wrinkles, skin laxity, and irregularities of the skin texture. Participants that had not obtained RF or laser therapy in the last six months and were authorized to undergo follow-up appointments were enrolled via informed consent.

### **Exclusion Criteria**

The study was restricted to participants with active facial infection, dermatitis, pregnancy, lactation, keloid tendency, recent chemical peel treatments, uncontrolled systemic illness or systemic retinoid treatment in the six months before the study.

## Intervention Protocol

### Monopolar RF

Radiofrequency treatment was done monopolar and continuous thermal energy was utilized with a range between 40-60J as far as patient tolerability and treatment indication was concerned. Each session underwent two to three treatment passes and four sessions were done.

### Bipolar RF

Energy settings of between 30-45 J were used to provide bipolar radiofrequency treatment to have controlled superficial dermal heating. Each session consisted of two to three passes, and all the participants had four treatment sessions.

### Fractional Microneedling RF

The fractional microneedling radiofrequency was done with insulated microneedles with depths of 0.5-2.0 mm depending on the size of the area of treatment and level of skin problem. The dose of energy delivery was 8 -15 mJ/pin and topical anesthesia was used (lasting about 25-30 minutes) before treatment. Stamping on was done in one to two stamping pass and there were four stamping sessions by participants.

It assessed such objective measurements as depth of wrinkles, three-dimensional images of the face, Corneometer measurements of skin moisture level and cutometer measurements of dermal elasticity. Subjective measures involved pain scoring with Visual Analog Scale (VAS), patient satisfaction with a five-point Likert scale, monitoring adverse events, wrinkle depth, 3D facial images, skin hydration measurement with Corneometer and dermal elasticity with Cutometer. Subjective measures consisted of pain scoring on the Visual Analog Scale (VAS), use of a five-point Likert scale to rate patient satisfaction and monitoring of adverse events.

Data were inputted and analyzed in SPSS version 26.0. The descriptive statistics were in terms of mean standard deviation and frequencies in terms of percentages. Quantitative comparisons between groups were done using one-way ANOVA and Tukey post hoc analysis. Categorical variables were done using chi-square and the exact fisher test. The statistical significance was deemed as  $p < 0.05$ .

Table 1 indicates that the age group of 36–45 years (40.3%) constituted the dominant group among the respondents followed by the age group 25–35 years with 36.4%. The majority of the participants were female (63.6%). Fitzpatrick type III and IV were most common skin types (39.0% vs 37.7%).

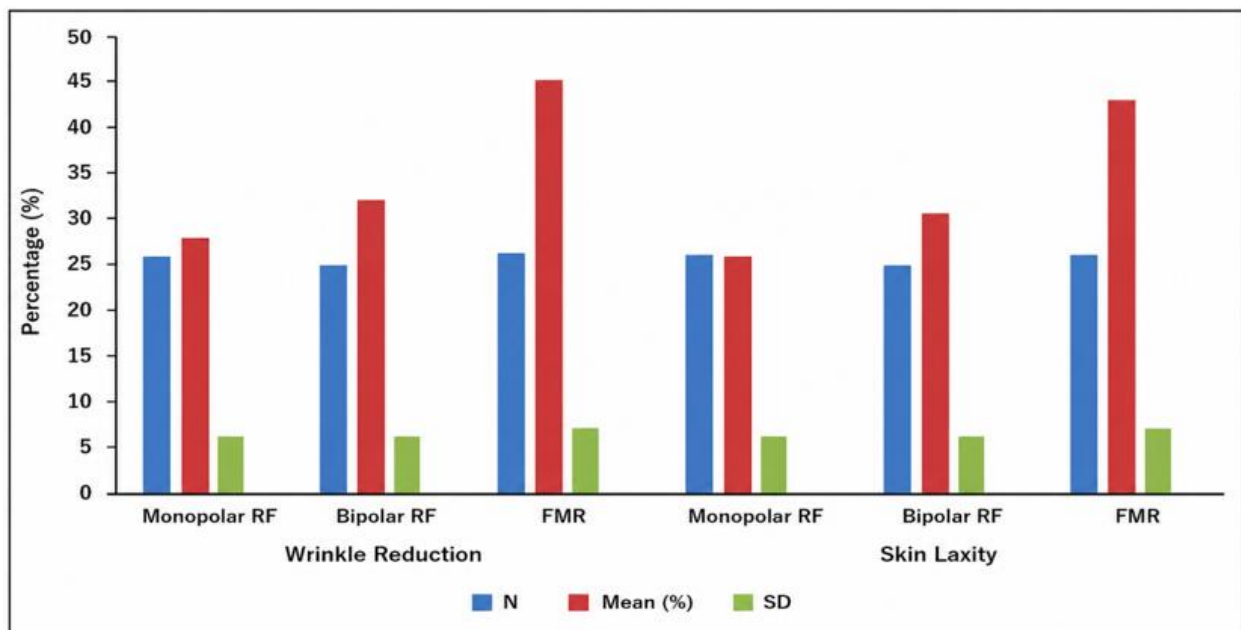
**Table 1** Demographic Characteristics of Study Participants

Variable	Frequency (n)	Percentage (%)
Age 25–35 years	28	36.4
Age 36–45 years	31	40.3
Age 46–60 years	18	23.3
Female	49	63.6
Male	28	36.4
Fitzpatrick III	30	39.0
Fitzpatrick IV	29	37.7
Fitzpatrick V	18	23.3

Table 2 illustrates that the mean improvement when looking at wrinkle reduction ( $45.6 \pm 7.4\%$ ) and skin laxity ( $42.8 \pm 6.9\%$ ) was the greatest with FMR group and the least with Monopolar RF group. Statistically significant differences between the treatments were observed for both parameters ( $p = 0.001$ ).

**Table 2** Descriptive Statistics and ANOVA Analysis of Wrinkle Reduction and Skin Laxity Among Treatment Groups

Parameter	Group	N	Mean (%)	SD	F-value	p-value
Wrinkle Reduction	Monopolar RF	26	28.4	6.2	18.72	0.001
Wrinkle Reduction	Bipolar RF	26	32.1	5.8	18.72	0.001
Wrinkle Reduction	FMR	26	45.6	7.4	18.72	0.001
Skin Laxity	Monopolar RF	26	25.7	5.9	16.54	0.001
Skin Laxity	Bipolar RF	26	30.3	6.1	16.54	0.001
Skin Laxity	FMR	26	42.8	6.9	16.54	0.001

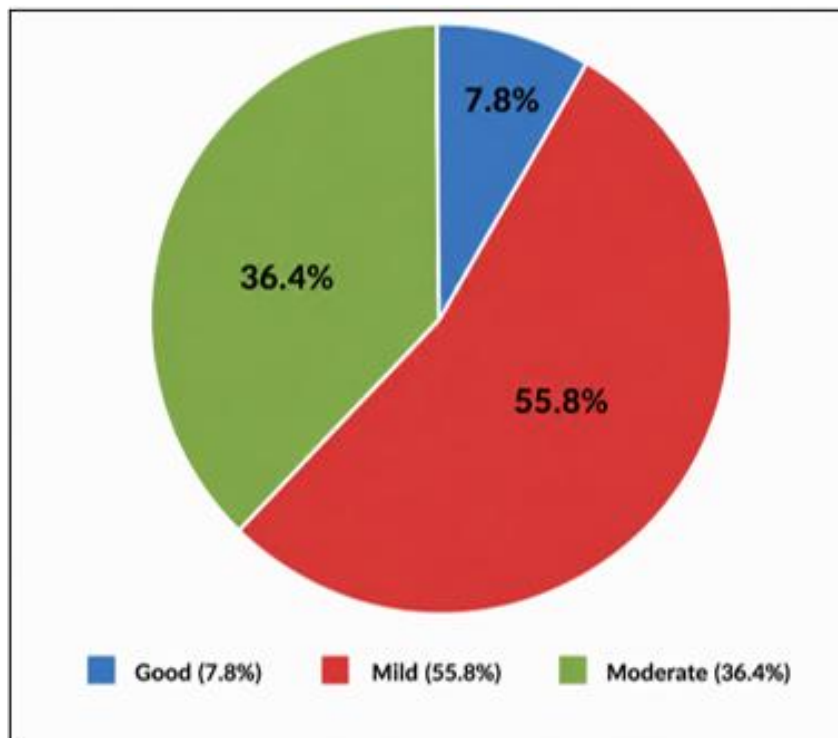


**Figure 1** The comparison of wrinkle reduction and skin laxity among Monopolar RF, Bipolar RF, and FMR treatments showed significant differences, with Fractional Microneedling RF demonstrating the highest clinical improvement and Monopolar RF showing the least effectiveness.

As seen in table 3, the FMR group had the greatest number of favorable outcomes with respect to PIH improvements (69.2%), followed by Bipolar RF (53.8%) and the lowest number of good improvements and comparatively high numbers of moderate or mild responses was seen with Monopolar RF.

**Table 3** Distribution of PIH Improvement Across Treatment Modalities

Treatment Modality	Good Improvement n (%)	Moderate Improvement n (%)	Mild Improvement n (%)
Monopolar RF	10 (38.5%)	11 (42.3%)	5 (19.2%)
Bipolar RF	14 (53.8%)	8 (30.8%)	4 (15.4%)
FMR	18 (69.2%)	6 (23.1%)	2 (7.7%)



**Figure 2** Distribution of post-inflammatory hyperpigmentation (PIH) improvement among patients, showing that mild improvement was most common (55.8%), followed by moderate improvement (36.4%), while only 7.8% of patients achieved good improvement.

Table 4 shows that erythema and edema appeared more often with FMR than Monopolar and Bipolar RF treatments, but no persistent post-inflammatory hyperpigmentation (PIH) were reported for any treatment modality.

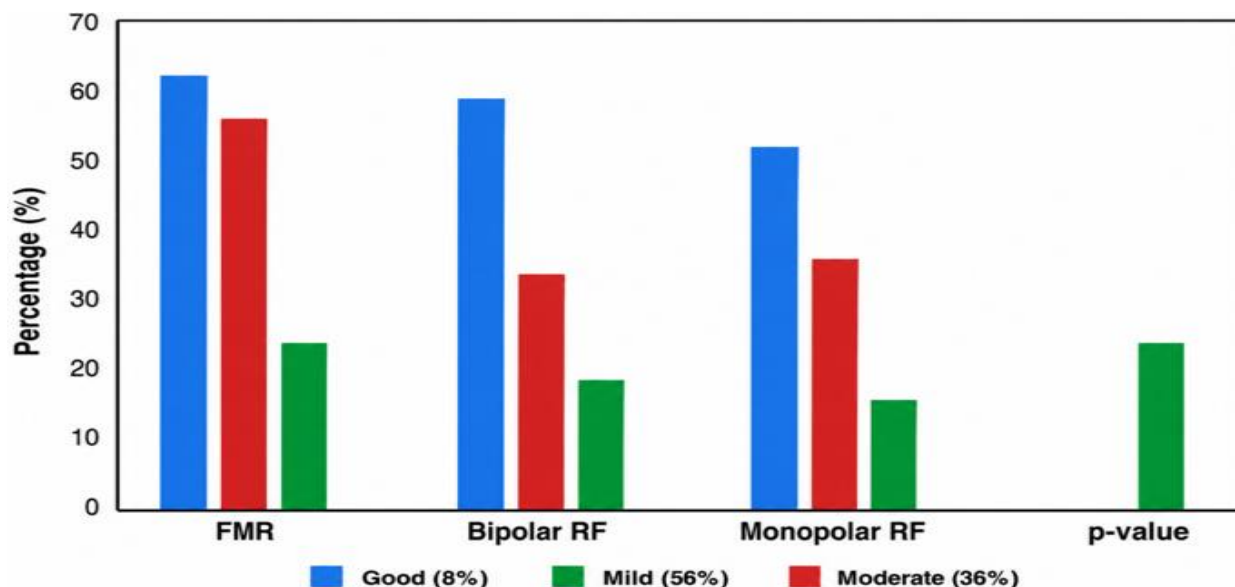
**Table 4** Comparative Incidence of Adverse Events Among Treatment Modalities

Adverse Event	Monopolar RF n (%)	Bipolar RF n (%)	FMR n (%)
Erythema	5 (19.2%)	8 (30.8%)	16 (61.5%)
Edema	4 (15.4%)	7 (26.9%)	14 (53.8%)
Persistent PIH	0 (0%)	0 (0%)	0 (0%)

Table 5 shows that the FMR group had a higher number of very satisfied patients (61.5%) and a lower number of dissatisfied patients when compared to Monopolar RF.

**Table 5** Distribution of Patient Satisfaction Across Treatment Modalities

Satisfaction Level	Monopolar RF	Bipolar RF	FMR
Very Satisfied	5 (19.2%)	10 (38.5%)	16 (61.5%)
Satisfied	12 (46.2%)	11 (42.3%)	8 (30.8%)
Neutral	6 (23.1%)	4 (15.4%)	2 (7.7%)
Dissatisfied	3 (11.5%)	1 (3.8%)	0 (0%)



**Figure 3** illustrates the comparative distribution of post-inflammatory hyperpigmentation (PIH) improvement among Monopolar RF, Bipolar RF, and FMR treatments, showing that FMR achieved the highest satisfaction scores, Bipolar RF demonstrated balanced efficacy and tolerability, while Monopolar RF showed comparatively lower satisfaction rates.

## Discussion

In the current study, clinical efficacy and safety of Bipolar RF, Fractional Microneedling RF, and Monopolar RF were assessed and compared, and used in Fitzpatrick III–V. The results indicated that each of the three treatment modalities was statistically significant, and made significant improvements on hyperpigmentation, wrinkles, skin texture, and skin laxity; though Fractional Microneedling RF was statistically more effective than the Monopolar RF and Bipolar RF treatment groups.

Fractional Microneedling RF showed a great reduction in wrinkles and skin laxity when compared with Monopolar RF and Bipolar RF (Table 2; Figure 1). Gold et al. (2012), Chae et al. (2015), and Pathmarajah et al. (2022) reported similar results and saw considerable dermal remodeling and stimulation of collagen following FMR treatments. The higher results of the current research could be explained by a combination of collagen stimulation effect caused by micro-needling and regulated radiofrequency energy input to dermis.

The current study also proved statistically significant enhancement in post-inflammatory hyperpigmentation in the patients using Fractional Microneedling RF (Table 3; Figure 2). Similar findings were reported by Kwon et al. (2018) who found a big difference in melanin index and severity of pigmentation after RF-based procedures. In contrast to traditional laser treatments, radiofrequency enhancers generate heating within the dermis without the direct attack of epidermal melanin and so less pigmentary issues are likely to arise in darker skin phototypes.

Bipolar RF showed a moderate improvement of the skin texture and pigmentation with a desirable safety profile. Such results correlate with those of Cho et al. (2015) who reported comparable clinical outcomes with Bipolar RF to that of fractional CO<sub>2</sub> laser treatment but with much lower rates of post-inflammatory hyperpigmentation.

Even though Fractional Microneedling RF had a relatively higher number of cases of transient erythema and edema, no one treatment group experienced the presence of persistent post-inflammatory hyperpigmentation (Table 4). This result has clinical implications as PIH has always been among the most alarming complications amid Fitzpatrick skin types III–V, Chae et al. (2015)

and Davis and Callender (2010) started by stating that PIH is usually temporary, mild, and controllable due to RF.

The scores of patient satisfaction were the highest in patients undergoing Fractional Microneedling RF even though pain scores were relatively higher (Table 5.5; Figure 5.4). This indicates that it is visible clinical improvement that patients are willing to sacrifice procedural discomfort in the short term. Monopolar RF showed relatively less satisfaction rates but were still applicable to the patients who want shorter time to heal and less intensive treatment.

Comprehensively, the results of the current research can be explained by increasing evidence that RF-based technologies are safe and efficient methods of treatment against hyperpigmentation, wrinkle reduction, and skin rejuvenation in Fitzpatrick skin type III-V individuals.

## Conclusion

The current study has found that fractional microneedling radiofrequency is the most acceptable treatment modality to enhance hyperpigmentation, wrinkle, skin texture and skin laxity in people with Fitzpatrick skin type III-V. Bipolar radio frequency showed moderate and clinically significant outcomes with a preferred balance of efficacy and tolerability. Compared to bipolar radiofrequency, monopolar radiofrequency was found to have relatively less clinical effectiveness yet retained the ability to be used by patients with minimal downtimes needing only mild rejuvenation.

No cases of persistent post-inflammatory hyperpigmentation was reported, and all the three modalities had acceptable safety profiles. The results confirm the involvement of using RF-based technologies as safe and effective to be applied in place of traditional laser treatments in darker skin types.

Standardized treatment protocols and outcomes over the long term should be determined with the help of further longitudinal studies with larger samples and longer follows.

## References

- Alhaddad, M., Wu, D. C., Bolton, J., Wilson, M. J., Jones, I. T., Boen, M., & Goldman, M. P. (2019). A randomized, split-face, evaluator-blind clinical trial comparing monopolar radiofrequency versus microfocused ultrasound with visualization for lifting and tightening of the face and upper neck. *Dermatologic Surgery*, 45(1), 131–139.
- Alexis, A. F., Sergay, A. B., & Taylor, S. C. (2007). Common dermatologic disorders in skin of color: a comparative practice survey. *Cutis*, 80(5), 387-394.
- Chae, W. S., Seong, J. Y., Jung, H. N., Kong, S. H., Kim, M. H., Suh, H. S., & Choi, Y. S. (2015). Comparative study on efficacy and safety of 1550 nm Er:Glass fractional laser and fractional radiofrequency microneedle device for facial atrophic acne scar. *Journal of cosmetic dermatology*, 14(2), 100–106. <https://doi.org/10.1111/jocd.12139>
- Cho, S. I., Chung, B. Y., Choi, M. G., Park, C. W., & Kim, H. O. (2015). Evaluation of the clinical efficacy and safety of 1550-nm fractional erbium-glass laser and fractional microneedling radiofrequency for the treatment of acne scars: A multicenter, randomized, split-face study. *Journal of Cosmetic Dermatology*, 14(2), 121–129. <https://doi.org/10.1111/jocd.12139>
- Davis, E. C., & Callender, V. D. (2010). Postinflammatory hyperpigmentation: a review of the epidemiology, clinical features, and treatment options in skin of color. *The Journal of clinical and aesthetic dermatology*, 3(7), 20–31.
- Gold, M. H., & Biron, J. A. (2012). Treatment of acne scars by fractional bipolar radiofrequency energy. *Journal of Cosmetic and Laser Therapy*, 87(6), 172-178.
- Grimes, P. E. (2009). Management of hyperpigmentation in darker racial ethnic groups. *Seminars in Cutaneous Medicine and Surgery*, 28(2), 77–85.
- Kwon, Hyuck & Choi, Sun & Jung, Jae & Park, Gyeong-Hun. (2018). Combined treatment of

melasma involving low-fluence Q-switched Nd:YAG laser and fractional microneedling radiofrequency. *Journal of Dermatological Treatment*, 30, 1-20. 10.1080/09546634.2018.1516858.

- Niaz, G., Ajeebi, Y., Alshamrani, H. M., Khalmurad, M., & Lee, K. (2025). Fractional Radiofrequency Microneedling as a Monotherapy in Acne Scar Management: A Systematic Review of Current Evidence. *Clinical, cosmetic and investigational dermatology*, 18, 19–29. <https://doi.org/10.2147/CCID.S502295>
- Pathmarajah, P., Peterknecht, E., Cheung, K., Elyoussfi, S., Muralidharan, V., & Bewley, A. (2022). Acne vulgaris in skin of color: a systematic review of the effectiveness and tolerability of current treatments. *The Journal of Clinical and Aesthetic Dermatology*, 15(11), 43.
- Tan, M. G., Jo, C. E., Chapas, A., Khetarpal, S., & Dover, J. S. (2021). Radiofrequency microneedling: a comprehensive and critical review. *Dermatologic Surgery*, 47(6), 755-761.
- Taylor, S. C. (Ed.). (2023). *Diagnosing Skin Disease in Skin of Color, An Issue of Dermatologic Clinics*, E-Book (Vol. 41, No. 3). Elsevier Health Sciences. Twice